

1 Einleitung

Durch die exponierte Lage der Schneidezähne im Pferdegebiss werden deren Erkrankungen durch Tierbesitzer leichter erkannt. Auch die Forschung zu Schneidezahnpathologien und -behandlungen bei Pferden schreitet weiter voran (Rawlinson & Carmalt, 2014).

Die häufigsten Diagnosen von Schneidezahnerkrankungen sind traumatische Insulte, Malformationen, wie Brachy- oder Prognathie, die die Schneidezahngesundheit beeinträchtigen, und Equine Odontoclastic Tooth Resorption and Hypercementosis (EOTRH) (Dixon & Dacre, 2005; Earley & Rawlinson, 2013; Rawlinson & Earley, 2013).

EOTRH ist eine schmerzhafte und progressiv verlaufende Erkrankung der Inzisivi und Canini, die vornehmlich bei Pferden ab einem Alter von 15 Jahren auftritt (Staszyk et al., 2008) und deren Schweregrad mit fortschreitendem Alter ansteigt (Henry et al., 2017; Rehr et al., 2018). Die klinische Symptomatik betroffener Pferde ist vielfältig und zeigt sich unter anderem durch Schmerzhaftigkeit im Bereich der Inzisivi, Probleme bei der Futteraufnahme, Inappetenz und daraus folgendem Gewichtsverlust. Ebenfalls können Kopfscheue und Headshaking sowie vermehrtes Speicheln und Verhaltensauffälligkeiten, wie Spielen mit dem Tränkwasser oder Wetzen der Zähne an der Stalleinrichtung, auftreten (Earley & Rawlinson, 2013; Pearson et al., 2013; Rahmani et al., 2019).

In der klinischen Maulhöhlenuntersuchung fallen betroffene Zähne mit steileren Aufbisswinkeln oder Malokklusionen, Gingivitis, gingivalen Fisteln, Hyperplasien oder Retraktion der Gingiva sowie Parodontitis, Zahnstein, knolligen Auftreibungen der Zahnwurzelbereiche, Zahnfrakturen und lockeren Zähnen auf (Staszyk et al., 2008; Earley & Rawlinson, 2013; Grier-Lowe & Anthony, 2015; Smedley et al., 2015). Die röntgenologische Untersuchung gilt als Schlüssel zur Diagnosestellung der EOTRH (Hole & Staszyk, 2018). Hierbei werden intraorale Röntgenaufnahmen angefertigt. Die beiden Hauptmerkmale der Erkrankung zeigen sich als resorptive Läsionen der Zahnhartsubstanzen und knollige, röntgendichte Umfangsvermehrungen der

intraalveolären Zahnanteile (Staszuk et al., 2008). Aber auch Zahnfrakturen, Verlust des parodontalen Spalts, Läsionen im Alveolarknochen und Osteomyelitis können beobachtet werden (Earley & Rawlinson, 2013; Hole & Staszuk, 2018; Rehr et al., 2018). Besonders im frühen Stadium der Erkrankung stellt die röntgenologische Diagnose eine Herausforderung dar (Hole & Staszuk, 2018; Albers et al., 2022a). Da betroffene Pferde eine unterschiedliche Schmerzsymptomatik zeigen können, sollte das Therapiemanagement stets in Abhängigkeit der klinischen und röntgenologischen Befunde individuell angepasst werden. Auch eine Differenzierung von EOTRH zu anderen Krankheitsbildern mit ähnlicher Symptomatik ist notwendig (Albers et al., 2022b).

In der pferdemedizinischen Praxis wird neben der zweidimensionalen Röntgenbildgebung zunehmend auch die computertomographische Untersuchung eingesetzt. Diese gilt als Goldstandard der Diagnostik und chirurgischen Planung für Erkrankungen am Kopf des Pferdes (Dakin et al., 2014; Strauch et al., 2019). Ein großer Vorteil der Computertomographie (CT) gegenüber konventioneller röntgenologischer Bildgebung ist die überlagerungsfreie, dreidimensionale Darstellung komplexer anatomischer Strukturen. Allerdings sind der Auflösung im Submillimeterbereich Grenzen gesetzt. Im Gegensatz dazu können Mikro-Computertomographie (μ CT) Systeme Voxelgrößen erzeugen, die annähernd 1.000.000 mal kleiner sind als jene in der konventionellen CT (Swain & Xue, 2009).

Allerdings bleiben der μ CT-Bildgebung Untersuchungen an extrahierten Zähnen vorbehalten. In der humanen Zahnmedizin werden vielfältige Fragestellungen mithilfe der μ CT untersucht. Neben der Detektion von kariösen Läsionen (Oliveira et al., 2019) lassen sich die Zahnschmelzdicke und der Mineraliengehalt eines Zahns messen (Swain & Xue, 2009). Auch im Bereich der Wurzelkanalanatomie und endodontischen Therapie sowie der Implantologie findet die μ CT Anwendung (Swain & Xue, 2009).

In der Pferde Zahnmedizin finden sich sowohl anatomische und biomechanische als auch pathologische μ CT-Studien. Kopke et al. (2012) beschreiben die Morphologie des endodontischen Systems an 65 Backenzähnen, während Englisch et al. (2018) und Schrock et al. (2013) detaillierte anatomische Untersuchungen an equinen

Schneidezähnen vorgenommen haben. Dabei beschreiben sie neben der Anatomie der Zahnhartsubstanzen und der Pulparäume auch altersabhängige Veränderungen der Zähne. Neben diesen Studien wurden Untersuchungen zur Biomechanik und Belastung während des Kauvorgangs mithilfe von Finite Element Analysen durchgeführt (Cordes et al., 2012; Schrock et al., 2013a; Schrock et al., 2013b). Allerdings beschränken sich μ CT-Untersuchungen aufgrund der Größe der verfügbaren Gantry auf extrahierte Zähne.

Ein Ziel der vorliegenden Arbeit war es, die Möglichkeit der röntgenologischen Früherkennung von resorptiven und EOTRH bedingten Läsionen an equinen Schneidezähnen im Vergleich zu μ CT-Analysen sowie klinischen und makroskopischen Untersuchungen zu evaluieren.

Die röntgenologische (Verdachts-)Diagnose der EOTRH kann histologisch abgesichert werden. In der histologischen Untersuchung betroffener Zähne finden sich resorptive Bereiche im Zahnhartgewebe sowie Ablagerungen von reparativem, irregulär gestaltetem Zement mit welligen basophilen Wachstumslinien (Staszuk et al., 2008). Die resorptiven Lakunen, sogenannte Howship Lakunen, entstehen durch aktivierte Odontoklasten und dehnen sich in allen drei Zahnhartsubstanzen sowie teilweise bis in die Pulpenhöhle aus (Staszuk et al., 2008; Smedley et al., 2015). Die Bildung von irregulärem Zement durch Zementoblasten wird als reparative Reaktion auf die resorptiven Stimuli angesehen. Anders als bei resorptiven Zahnerkrankungen anderer Spezies, scheint sich das parodontale Ligament des equinen Zahnhalteapparates wieder an die irreguläre Zementoberfläche des erkrankten Zahns anheften zu können (Staszuk et al., 2008). Des Weiteren finden sich histologisch Anzeichen einer parodontalen Erkrankung, die sich in Form von lymphoplasmazellulärer Infiltration und Fibrose des parodontalen Ligaments darstellen (Smedley et al., 2015).

Jedoch können auch andere Prozesse ursächlich für resorptive Läsionen im Bereich der Zahnhartsubstanzen sein. In der Humanzahnmedizin wird Zahnresorption definiert als Zustand, der assoziiert mit einem physiologischen oder pathologischen Stimulus in einem Verlust von Zahnhartsubstanz oder sogar Knochen endet (American

Association of Endodontist, 2020). Im brachydonten Gebiss werden verschiedene Arten der Zahnresorption unterschieden (Peralta et al., 2010; American Association of Endodontist, 2020). Eine dieser Arten ist die sogenannte '*external surface resorption*', die durch eine vorübergehende Odontoklastenaktivierung ausgelöst wird, selbstlimitierend ist und als nicht pathologisch eingestuft wird (Andreasen, 1970; Ne et al., 1999; Aidos, 2018). Daher erfordert diese Art der Resorption auch keine Behandlung (Ne et al., 1999; Henry et al., 2017). Weitere Formen der Zahnresorption im brachydonten Gebiss sind '*external inflammatory root resorption*' und '*external cervical root resorption*'. Diese sind zwar nicht schmerzhaft, zeigen jedoch einen progressiven, nicht selbstlimitierenden Verlauf und sind daher therapiewürdig (Andreasen, 1970; Ne et al., 1999; von Arx et al., 2009; Peralta et al., 2010; Henry et al., 2017). Diese Pathologien ähneln dem Krankheitsbild der EOTRH durch die Ausdehnung der odontoklastischen Resorptionen sowie durch das Vorkommen von Entzündungszellinfiltraten im parodontalen Gewebe und die Bildung von Granulationsgewebe (Ne et al., 1999). Obwohl die Diagnose der verschiedenen Zahnresorptionen in der Humanzahnmedizin in der Regel röntgenologisch gestellt wird (Aidos, 2018), kann eine abschließende Unterscheidung der Resorptionstypen nur histologisch erfolgen (Peralta et al., 2010).

Demgemäß wurde als zweites Untersuchungsziel der vorliegenden Studie angestrebt, röntgenologisch und im μ CT detektierte Zahnresorptionen histologisch zu evaluieren und so EOTRH bedingte von andersartigen Läsionen zu unterscheiden.

2 Ergebnisse

2.1 Publikation I

Early incisor lesions and Equine Odontoclastic Tooth Resorption and Hypercementosis: Reliability of radiographic findings

Published in: Equine Veterinary Journal published by John Wiley & Sons Ltd on behalf of EVJ Ltd.

Received: 15 September 2021 | Accepted: 10 March 2022

Louisa Albers¹ | Jonas Albers² | Christian Dullin² | Carsten Staszky³ | Astrid Bienert-Zeit¹

¹Clinic for Horses, University of Veterinary Medicine Hannover, Foundation, Hannover, Germany

²Institute for Diagnostic and Interventional Radiology, University Medical Centre Göttingen, Göttingen, Germany

³Faculty of Veterinary Medicine, Institute of Veterinary-Anatomy, -Histology and -Embryology, Justus-Liebig- University Gießen, Gießen, Germany

Summary

Background: In clinical practice, early diagnosis of Equine Odontoclastic Tooth Resorption and Hypercementosis (EOTRH) and other resorptive incisor diseases is difficult to achieve. The radiographic appearance of subtle pathological changes has not been described in detail and might be confused with age-related changes.

Objectives: The study was performed to define typical radiographic signs of early incisor lesions and to evaluate the reliability of the radiographic findings.

Study design: Descriptive and comparative study using post mortem clinical, radiographic, macroscopic and μ CT examination.

Methods: The incisor region of 20 cadaveric horse heads, divided into three different age groups, was examined visually and by palpation. Intraoral radiographs were taken. After extraction, each incisor was macroscopically evaluated. Micro-computed tomography (μ CT) scans were obtained. These scans were processed with Scry (v6.0, Kuchel & Sautter GbR) to obtain surface meshes which then were transferred to Meshlab (ISTI-CNR, version 2016.12). Attached tissues were virtually removed and surface curvature was computed to visualise and evaluate the quantity of unevenness (roughness) of the teeth's surface. Scoring systems for each diagnostic modality were developed. Scores were compared to describe and evaluate the radiographic appearance of early incisor lesions.

Results: The prevalence and severity of incisor lesions increased with age. Early, subtle lesions develop on the palatal/lingual side of incisors. While radiographically detected lesions were confirmed macroscopically and on the μ CT scans, numerous teeth which were radiographically classified as healthy displayed lesions by macroscopic inspection (13.7%) and μ CT analysis (58.1%).

Main limitations: Cadavers were studied and dental history was unknown.

Conclusions: The detection of early and subtle incisor lesions indicating first signs of EOTRH on dorsoventral intraoral radiographs is limited due to the typical localization of the lesions on the palatal/lingual side of the incisors.

Early incisor lesions and Equine Odontoclastic Tooth Resorption and Hypercementosis: Reliability of radiographic findings

Louisa Albers¹  | Jonas Albers² | Christian Dullin² | Carsten Staszuk³ | Astrid Bienert-Zeit¹

¹Clinic for Horses, University of Veterinary Medicine Hannover, Foundation, Hannover, Germany

²Institute for Diagnostic and Interventional Radiology, University Medical Centre Göttingen, Göttingen, Germany

³Faculty of Veterinary Medicine, Institute of Veterinary-Anatomy, -Histology and -Embryology, Justus-Liebig-University Gießen, Gießen, Germany

Correspondence

Louisa Albers, Clinic for Horses, University of Veterinary Medicine Hannover, Foundation, Hannover, Germany.
Email: louisa.albers@tiho-hannover.de

Funding information

This study has received financial support from the IGFP (Internationale Gesellschaft zur Funktionsverbesserung der Pferde Zähne e.V.).

Summary

Background: In clinical practice, early diagnosis of Equine Odontoclastic Tooth Resorption and Hypercementosis (EOTRH) and other resorptive incisor diseases is difficult to achieve. The radiographic appearance of subtle pathological changes has not been described in detail and might be confused with age-related changes.

Objectives: The study was performed to define typical radiographic signs of early incisor lesions and to evaluate the reliability of the radiographic findings.

Study design: Descriptive and comparative study using post mortem clinical, radiographic, macroscopic and μ CT examination.

Methods: The incisor region of 20 cadaveric horse heads, divided into three different age groups, was examined visually and by palpation. Intraoral radiographs were taken. After extraction, each incisor was macroscopically evaluated. Micro-computed tomography (μ CT) scans were obtained. These scans were processed with Scry (v6.0, Kuchel & Sautter GbR) to obtain surface meshes which then were transferred to Meshlab (ISTI-CNR, version 2016.12). Attached tissues were virtually removed and surface curvature was computed to visualise and evaluate the quantity of unevenness (roughness) of the teeth's surface.

Scoring systems for each diagnostic modality were developed. Scores were compared to describe and evaluate the radiographic appearance of early incisor lesions.

Results: The prevalence and severity of incisor lesions increased with age. Early, subtle lesions develop on the palatal/lingual side of incisors. While radiographically detected lesions were confirmed macroscopically and on the μ CT scans, numerous teeth which were radiographically classified as healthy displayed lesions by macroscopic inspection (13.7%) and μ CT analysis (58.1%).

Main limitations: Cadavers were studied and dental history was unknown.

Conclusions: The detection of early and subtle incisor lesions indicating first signs of EOTRH on dorsoventral intraoral radiographs is limited due to the typical localisation of the lesions on the palatal/lingual side of the incisors.

This is an open access article under the terms of the Creative Commons Attribution-NonCommercial-NoDerivs License, which permits use and distribution in any medium, provided the original work is properly cited, the use is non-commercial and no modifications or adaptations are made.

© 2022 The Authors. *Equine Veterinary Journal* published by John Wiley & Sons Ltd on behalf of EVJ Ltd.

KEYWORDS

 μ CT, dentistry, EOTRH, horse, incisors, radiography, teeth

1 | INTRODUCTION

Equine odontoclastic tooth resorption and hypercementosis (EOTRH) is a frequently diagnosed painful and progressive disease that affects the incisors of aged horses.¹ Horses with EOTRH show oral pain, masticatory problems, weight loss and behavioural changes.² Oral examination and radiography are recommended to diagnose EOTRH.^{3,4} Findings of the oral examination include gingivitis, fistula formation, gingival recession, deposition of calculus, tooth mobility and/or subgingival swellings.^{1,5,6}

Radiologically tooth resorption and bulbous enlargement of the intraalveolar part of the tooth are the main features of the disease¹; however, loss or widening of the periodontal space and changes in the alveolar bone and tooth fractures are also frequently observed.^{3,6} Especially in early stages of the disease, radiographs can be challenging to interpret.³

To further characterise the radiological signs of equine incisor diseases, Henry et al⁷ evaluated radiographs of 169 horses by applying a classification system for resorptive lesions established in man and dogs. They also documented the prevalence of hypercementosis in these teeth. Rehl et al⁸ examined radiographs from 142 horses over 10 years of age and found a high radiological prevalence

(62-94%) of EOTRH in an equine population in north-east Germany. However, there is a lack of reliable radiological parameters that indicate initial pathological resorptive processes.

Computed tomography (CT) avoids superimposition of complex anatomical structures, but fails to display structural changes on a sub-millimetre level. Micro-computed tomography (μ CT) detects micro-changes of dental hard substances reliably and has already been used to describe equine incisor anatomy in detail.^{9,10} However, μ CT is restricted to post-mortem investigation of isolated teeth.

The goal of the current study was to evaluate the possibility to detect early stages of resorptive lesions in equine incisors by means of radiography. Therefore, radiographic findings were correlated with clinical findings, and detected radiographic changes were reassessed by μ CT analyses and macroscopic inspection of extracted teeth.

2 | MATERIALS AND METHODS

Twenty horse heads of different breeds and different sex were examined. The horses' age was determined from ID documents and they were separated into three age groups: (I) 9-14 years ($n = 5$), (II) 15-19 years ($n = 7$) and (III) 20 years and older ($n = 8$, Table 1).

	Horse #	Age	Sex	Breed	'Clinical score'
Age group I	1	9	Mare	Haflinger	Healthy
	2	10	Mare	Draft horse	Healthy
	3	12	Mare	Draft horse	Healthy
	4	14	Gelding	Warmblood	Healthy
	5	14	Mare	Haflinger	Healthy
Age group II	6	17	Mare	Warmblood	Healthy
	7	18	Gelding	Warmblood	Healthy
	8	18	Stallion	Friesian horse	EOTRH
	9	19	Gelding	Icelandic horse	EOTRH
	10	19	Mare	Welsh pony	EOTRH
	11	19	Mare	Draft horse	Suspicious
	12	19	Mare	Warmblood	Suspicious
Age group III	13	20	Gelding	Warmblood	Suspicious
	14	21	Mare	Warmblood	Healthy
	15	23	Mare	Arabian horse	Suspicious
	16	22	Mare	Warmblood	EOTRH
	17	23	Mare	Warmblood	EOTRH
	18	26	Mare	Icelandic horse	Suspicious
	19	27	Mare	Icelandic horse	Suspicious
	20	27	Mare	Warmblood	EOTRH

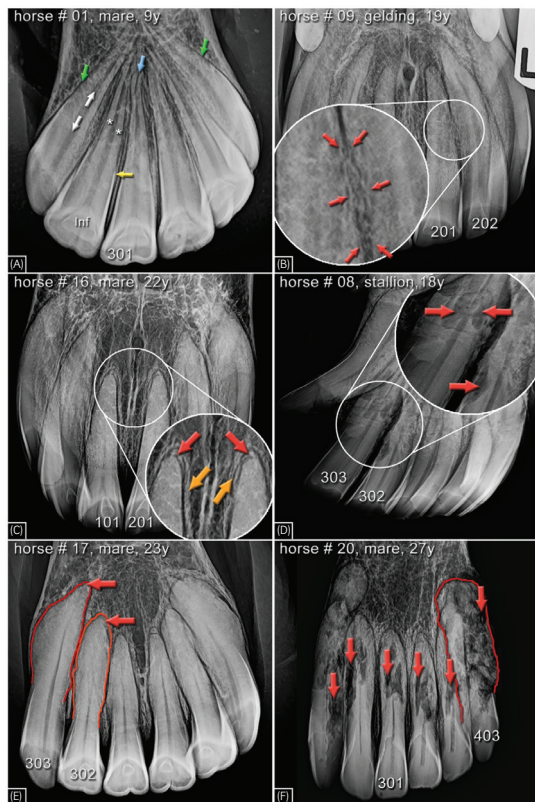
TABLE 1 Signalment and 'clinical score'

Ten horses were euthanised in the Clinic for Horses of the University of Veterinary Medicine Hannover, Germany due to non-dental reasons and ten horses were slaughtered at abattoirs. No information on previous dental treatments or diseases was available.

The incisor region of each separated head was examined visually and by palpation by one researcher (LA). In the following, this procedure is referred to as 'clinical examination'/'clinical scoring'. Seven parameters were assessed using a scoring system to determine the 'clinical' status of the incisor region (ie fistulae, gingival recession, clinically visible bulbous enlargement of the alveolar region, calculus, gingivitis, abnormalities of incisor angulation and tooth mobility). An overall 'clinical' score was calculated for each horse to group them into healthy, suspicious and EOTRH affected (Table S1).

Intraoral dorsoventral radiographs of the upper and lower incisors were taken (Gierth HF 1000, Gierth X-Ray International GmbH and Fujifilm DR-ID 300 CL APL Software V11.0, Fujifilm Europe GmbH). If the canine teeth in the lower jaw superimposed the corner incisors, additional oblique views were taken. For the evaluation of the radiographs, a scoring system was established including three parameters (shape, structure and surface of the tooth) (Table S2) and each tooth ($n = 236$) was individually graded into the following groups: healthy, suspicious, moderate EOTRH, severe EOTRH (Figure 1). Scoring was independently performed by four examiners (LA, JA, CD, AS) who were blinded to the horses' identity. Concerning the overall scores, while testing the inter-rater reliability, at least fair agreement was found in all compared combinations of raters. Only

FIGURE 1 Selected intraoral radiographs demonstrating typical features of healthy (A) and diseased (B-F) incisor arcades. (a) Several anatomical details are visible. Green arrows: periodontal space and alveolar bone (lamina dura), white arrows: pulp canal, white asterisks: dental root (dentin and cementum), yellow arrow: apical rim of the peripheral enamel, blue arrow: apical foramen, Inf: Infundibulum. (B) Mild irregularities of the dental surface of the intraalveolar aspects of teeth 201 and 202 (red arrows). The interdental space is not visible. (C) First incisors (101, 102) showing blunted root tips (red arrows) and mild opacity (suspected sclerosis) of the alveolar bone (yellow arrows). (D) Severe irregularities of the tooth's surface and structure (red arrows) in teeth 302 and 303. (E) Tooth 302 showing shortening and moderate enlargement of the intraalveolar aspect of the tooth (clinical crown remains wider than the intraalveolar part), tooth 303 shows a marked enlargement (intraalveolar part is wider than the clinical crown). Red arrows indicate blunted root tips. (F) All teeth show severe structural alterations (red arrows). The highlighted outline of tooth 403 indicates a severe alteration of the tooth shape (intraalveolar part wider than the clinical crown)



about 10% of the ratings differed in 2 score grades. Therefore, the averages of the raters' scores were calculated.

Subsequently all teeth ($n = 236$) were carefully extracted with routine dental extraction instruments to reduce iatrogenic damage of the teeth's outer surface and were stored in neutral buffered formalin 4%.

For macroscopic assessment, one researcher (ABZ) evaluated every tooth using a scoring system based on tooth shape, surface and structure (Table S3). Each tooth was assigned to one of the following classes: healthy, suspicious, moderate EOTRH, severe EOTRH. The examiner was blinded to the horses' identity.

The extracted teeth were then scanned in a micro-computed tomography system (QuantumFX, PerkinElmer) using an isotropic voxel size of 80 μm . A tube voltage of 90 kV and current of 200 μA was used. The complete teeth were inspected for pathological changes. All regions suspicious for such changes were observed in the palatal/lingual area. The data sets were processed with Scry (v6.0, Kuchel & Sautter GbR) to obtain surface meshes using a standard marching cubes algorithm. These meshes were created from the apical 5%-50% of the tooth's length, visualising the palatal/lingual area (Figure 2). The obtained meshes were transferred to MeshLab (ISTI-CNR) to remove attached tissue and to compute surface curvature for quantifying the roughness of the teeth's surface.

The resulting roughness values were then transferred from MeshLab to Excel (Microsoft Corporation) and the average of the absolute deviations of those data points from their mean was calculated. The obtained images visualising the roughness of the teeth's surface were reviewed and those teeth showing significant lesions from the extraction process were excluded ($n = 50$). The remaining images ($n = 186$) were evaluated in terms of distribution of roughness and whether the tooth showed a bulbous enlargement or not. This evaluation was conducted independently by three examiners (LA, JA, ABZ) who were blinded to the horses' identity and the mean score was calculated.

A score based on three parameters (roughness value/ ΔVEDEV value, distribution of roughness and bulbous enlargement) was used to sort the teeth into the following categories: healthy, suspicious, moderate EOTRH and severe EOTRH (Figure 3; Table S4).

The radiographic scores were compared with the macroscopic and μCT scores. To test the symmetry of these contingency tables, Bowker's test was conducted with SAS Enterprise Guide (version 7.1, SAS Institute Inc) and to measure the level of agreement between the different imaging modalities the concordance index kappa was used. The interpretation of those kappa values was conducted as followed: 0-0.2 none to slight, 0.21-0.39 fair, 0.4-0.59 moderate, 0.6-0.79 substantial, 0.8-1 almost perfect level of agreement.^{11,12}

3 | RESULTS

3.1 | Clinical assessment

All horses of age group I were classified as healthy along with two horses from age group II and one horse from age group III. Horses classified as either suspicious for EOTRH or affected by EOTRH were all older than 18 years of age (Table 1).

3.2 | Evaluation of radiographic, macroscopic and μCT assessment

According to the radiographic evaluation, 10.2% of all investigated teeth were classified as affected by EOTRH (8.9% moderately affected, 1.3% severely affected). In contrast, according to the μCT evaluation, 69.3% were recognised as affected by EOTRH (53.2% moderately affected, 16.1% severely affected; Table 2).

A comparison of the findings of the different imaging modalities is shown in Figure 4.




FIGURE 2 Processing of μCT images, 22-year-old mare, tooth 103, palatal surface. (A) μCT reconstruction with markers for 0%, 5%, 50% and 100% of the tooth's total length, (B) surface mesh obtained by Scry, (C) visualised curvature data set by MeshLab, white: smooth surface, red: invaginations of the surface, blue: protrusions of the surface